

A Rare Case of Vesico Uterine Fistula

Fatma M. Rentiya¹, Ajesh N. Desai²

Abstract

Here in, we are reporting a case of 24 year old female with vesico-uterine fistula (VUF) following repeat cesarean section who had presented with complaint of passing urine without any sensation of bladder fullness & menuria (menses in urine) along with urinary tract infection ; her whole diagnostic workup & repair of fistula by laparoscopy with outcome of management is mentioned.

Keywords: VUF; Menuria; LSCS; Laparoscopy.

Introduction

VUF constitutes 1 to 4% of all cases of genitourinary fistulas [1,2]. 83 to 93% cases follow caesarean section [3,4,5]. Chances of occurring VUF are more after repeat caesarean section rather than after primary [6,7]. Common presenting complaints in patients with VUF are menuria & urinary incontinence [8]. Diagnosis made by imaging after opacification of bladder or uterus [9]. Laparoscopic repair of VUF is safe & effective with successful outcome [10]. Advantages of laparoscopic repair are quicker convalescence, shorter hospital stay, better cosmetics & Similar success rates to open surgery [11,12,13,14]. Success rate of conservative management in case of VUF is < 5% [15]

Case Report

History

A 24 year old female presented at gynaecology OPD of GMERS, Sola with complaint of passing urine without sensation of bladder fullness & menuria since last LSCS done 8 months back. Patient had previous 2 LSCS. Patient had history of bladder injury during 2nd LSCS & urinary catheter had been kept for 21 days. History of leakage of blood stained urine from side of the bag. Conservative management had been given which had not been successful.

Investigations

Urine was sent for routine microscopy & culture sensitivity which show presence of E.Coli (Image 1). A methylene blue dye test was done which confirmed the presence of the fistula (Image 2). CT scan showed presence of a fistulous communication between bladder & uterus (Image 3). Cystoscopy revealed the presence of an opening in the supratrifurcal area of the bladder & showed VUF (Image 4). Hysteroscopy also revealed the vesico uterine fistula (Image 5).

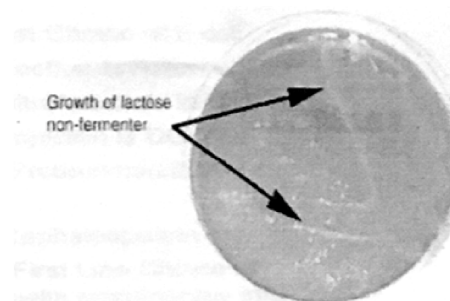


Image 1: Urine culture shows growth of E.coli

¹Second Year Resident
Doctor, Department of
Obstetrics & Gynaecology,
GMERS Medical College,
Sola, Ahmedabad, Gujarat
380081, India.

²Professor & Head,
Department of Obstetrics
and Gynecology, GMERS
Medical College, Sola,
Ahmedabad, Gujarat
380081, India.

Corresponding Author:
Fatma M. Rentiya,
Second Year Resident
Doctor,
Department of Obstetrics &
Gynaecology, GMERS
Medical College, Sola,
Ahmedabad, Gujarat
380081, India.
E-mail:
fatmarentia@icloud.com

Received on 27.09.2018,
Accepted on 16.10.2018

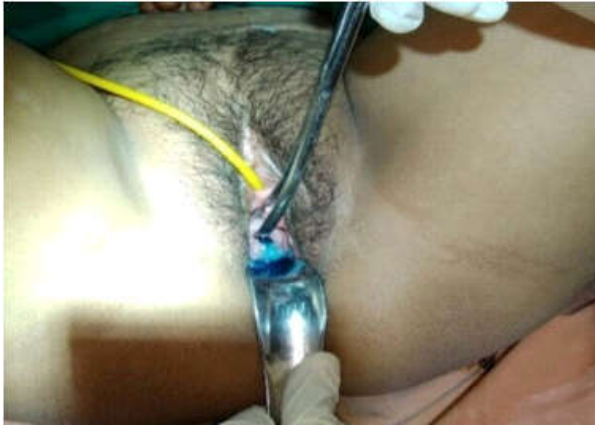

Image 2: In Methylene blue dye test, dye came out of cervix after 300 ml of dye had been instilled into bladder via catheter

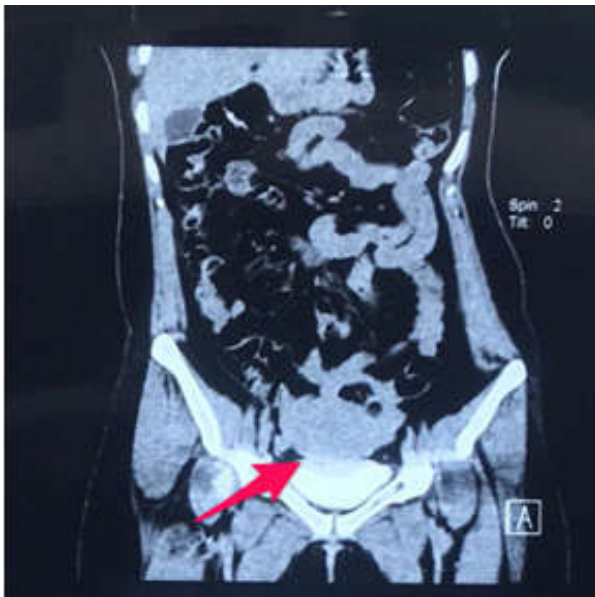

Image 3: CT Scan - Arrow shows VUF

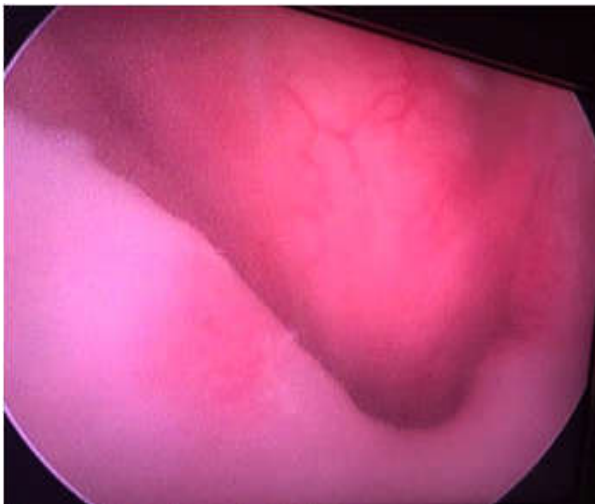


Image 4: Cystoscopy shows VUF with uterus above and bladder below



Image 5: Hysteroscopy shows VUF

Laparoscopic repair of VUF

Patient was placed in lithotomy position. Using 4 ports (a single main supraumbilical port of 11mm diameter for camera & 3 accessory ports each of 5mm diameter), dissection was started in vesico-uterine fold. Bladder was densely adherent to uterus which was released.

Fistula tract separated & excised. Urinary bladder was closed in 2 layers & uterus closed in single layer via V-LOC 2-0 with interposition of omentum at anterior wall of uterus below suture line. A silicon catheter was kept postoperatively to drain bladder for 14days.

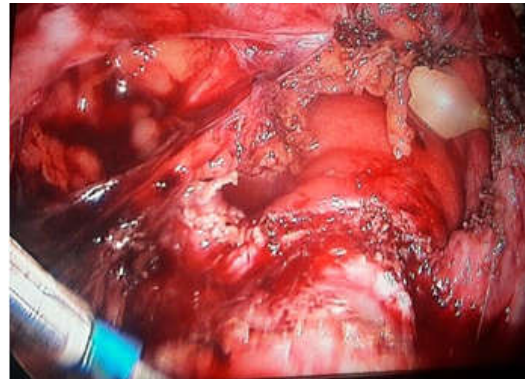


Image 6: Shows vesical part of fistula with Foley's bulb in bladder

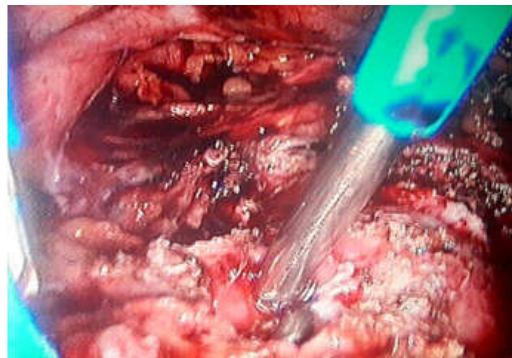


Image 7: Metallic part of uterine manipulator seen in uterine part of fistula

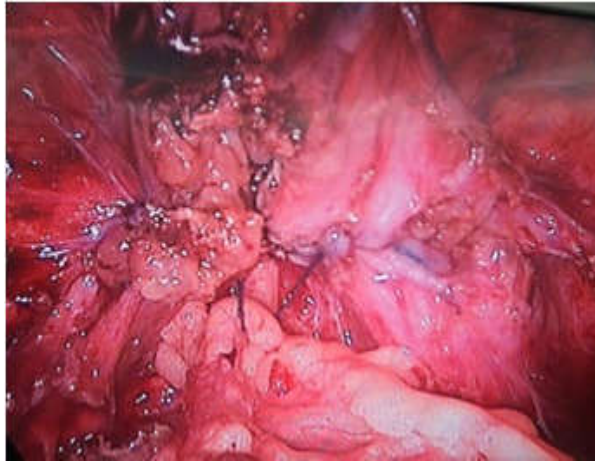


Image 8: Final closure with V-LOC suture with interposition of omentum between uterine & vesical parts

Results

There was no urinary leakage after laparoscopic repair of VUF. Menuria resolved after the surgery.

Discussion

VUFs are rarest type of genito urinary fistulas & are one of the rare complication of LSCS. VUFs due to LSCS may be prevented by downward retraction of bladder, correct identification of anatomical landmarks while suturing & proper evaluation of intra operative hematuria. Intra operative diagnosis is gold standard in repairing VUF for allowing an immediate repair. Intra operative sonography can be done i.e. transvaginal sonography/transrectal sonography. VUF should be suspected when a multiparous woman with repeated caesarean section presents with menuria or a woman after lscs or gynaecological procedures presents with hematuria &/or urinary leakage. Diagnosis is confirmed by CT scan, cystoscopy & hysteroscopy. Surgery is mainstay & definitive treatment of VUF. Pregnancy rate after VUF repair 31.25% with rate of term deliveries 25% [16].

Conclusion

Laparoscopic VUF repair is safe & effective. It is successful method in terms of resolution of symptoms & restoration of patient's social life, physical & mental health.

Ethical Statement

Written informed consent of patient was obtained.

Conflict of Interest

None

References

1. Kilinc F, Bagis T. Unusual case of post-caesarean vesicouterine fistula (Youssef's syndrome) International journal of Urology. 2003;10(4):235-8.
2. Park QR, Kim TS. Sonographic diagnosis of VUF. Ultrasound in obstetric and gynaecology. 2003; 22(1):82-4.
3. Eisenkop S.M., Richman R., Platt L.D., Paul R.H. Urinary tract injury during Caesarean section. Obst Gynecol. 1982;60:591-596.
4. Buchholz N.P., Daly-Grandeau E., Huber-Buccholz M.M. Urological complications associated with caesarean section. Eur J Obstet Gynecol Reprod Biol. 1994;56:161-63.
5. Yossepowitch O., Baniel J., Livne P.M. Urological injuries during Cesarean section: intraoperative diagnosis and management. J Urol. 2004;172:196-99.
6. Jozwik M, Jozwick M, Lotocki W. VUF-an analysis of 24 cases from Poland-Int J Gynecol Obstet, 1997;5792: 169-72.
7. Hadzi-Djokic B, Pejic TP, Colovic VC. Vesicouterine fistula: report of 14 cases BJU Int 2007;100(6):1361-3.
8. Daniyan B, Sunday-Adeoye I, Ekwedigwe K, Dantani D, Eliboh M. Review of Vesicouterine Fistula at the National Obstetric Fistula Centre, Abakaliki, Nigeria. Gynecol Obstet (Sunnyvale) 2016;6:380. doi:10.4172/2161-0932.1000380.
9. Tarek Smayra, Michel A. Ghossain. VUFs: imaging findings in 3 cases; American journal of Roentgenology.
10. Sahbi Naouar, Salem Braiek, Rafik El Kamel. Laparoscopic repair of VUF: a case report & mini review of literature. J Curr Surg. 2016;6(3-4):75-77.
11. Ramalingam M, Senthil K, Pai M, Renukadevi R. Laparoscopic repair of vesicouterine fistula a case report. Int Urogynecol J Pelvic Floor Dysfunct 2008;19:731-3.
12. Chibber PJ, Shah HN, Jain P. Laparoscopic O'Conor's repair for vesico-vaginal and vesico-uterine fistulae. BJU Int 2005;96:183-6.
13. Das Mahapatra P, Bhattacharyya P. Laparoscopic intraperitoneal repair of high-up urinary bladder fistula : A review of 12 cases. Int Urogynecol J Pelvic Floor Dysfunct 2007;18:635-9.

14. Hemal AK, Kumar R, Nabi G. Post-cesarean cervicovesical fistula: Technique of laparoscopic repair. JUrol 2001;165:1167-8.
 15. Hadzi-Djokic JB, Pejic TP, Colovic VC. Vesico-uterine fistula: Report of 14 cases. BJU Int 2007;100:1361-3.
 16. Procaro AB, et al. Vesicouterine fistulas following cesarean section: report on a case, review and update of the literature. Int Urol Nephrol. 2002;34(3):335-44.
-

Instructions to Authors

Submission to the journal must comply with the Guidelines for Authors.
Non-compliant submission will be returned to the author for correction.

To access the online submission system and for the most up-to-date version of the Guide for Authors please visit:

<http://www.rfppl.co.in>

Technical problems or general questions on publishing with IJOG are supported by Red Flower Publication Pvt. Ltd's Author Support team (http://rfppl.co.in/article_submission_system.php?mid=5#)

Alternatively, please contact the Journal's Editorial Office for further assistance.

Editorial Manager
Red Flower Publication Pvt. Ltd.
48/41-42, DSIDC, Pocket-II
Mayur Vihar Phase-I
Delhi - 110 091(India)

Mobile: 9821671871, Phone: 91-11-22754205, 45796900, 22756995

E-mail: author@rfppl.co.in